

CLINICAL IMAGES

Radiographic Features of Ellis-Van Creveld Syndrome

M. Nasir Shamas, . M. Ashraf Ganie, Sanjeed Ahmed*

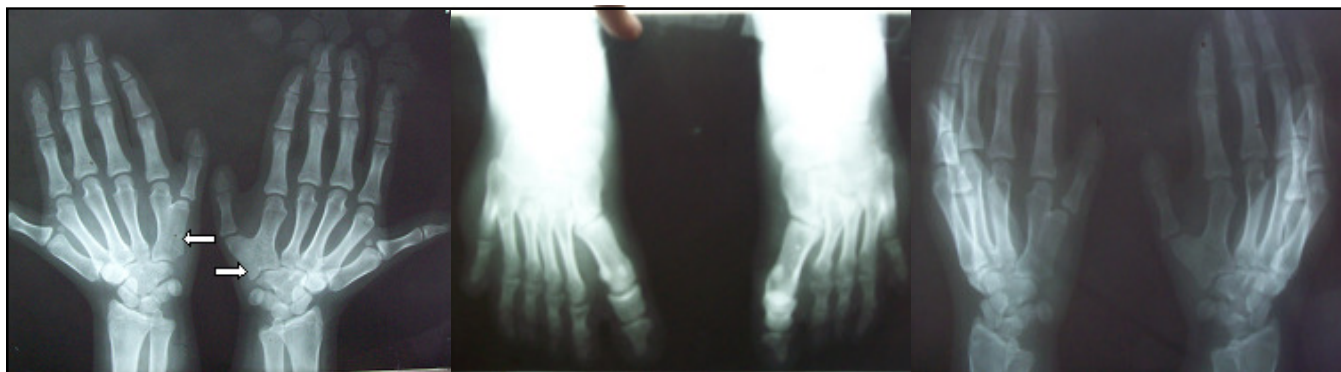


Fig: 1. X-Ray Both Hands Showing Fusion of Fifth And Sixth Metacarpal Bones And Polydactyly In Both Hands.

Fig 2. X-Ray Feet Showing Six Metatarsal Bones In Left Foot

Fig 3. X-Ray Hand Showing Bifid Metacarpals Due To Fusion of Fifth And Sixth Metacarpal Bones.

Ellis-van Creveld syndrome is a rare congenital genetic disorder having autosomal recessive inheritance. It is a syndrome affecting the Amish population of Pennsylvania in USA with prevalence rate of 1/5,000 live at birth. In non-Amish population, the birth prevalence is 7/1000000. The syndrome is characterized by bilateral postaxial polydactyly of the hands, chondrodysplasia of long bones resulting in acromesomelic dwarfism, ectodermal dysplasia affecting nails as well as teeth and congenital heart malformation. There were very rare reports (1,2,3) of this syndrome in dentistry. 16 year old girl, 4th in birth order with a history of polydactyly and neonatal death in one of her siblings, born of non-consanguineous marriage presented to our clinic for evaluation of short stature. On examination she had a height of 134 cms; upper segment 74 cms, lower segment 60 cms, with an arm span of 76 cms and waist circumference of 89 cms. She had hemidystrophy of the face on left side, large tongue, high arched palate; lips attached to the gums by 2 frenular bands, microdontia, congenitally missing teeth, peg like dysplastic teeth with caries, discolored, dystrophic and hypoplastic nails of fingers and toes, 6 digits in both hands (Fig: 1 & 3) and left foot (Fig-2) with syndactyly in left toe. Thus, our case had all these limb anomalies. The effective management of this syndrome will require a team which includes pedodontist, oral and maxillofacial surgeon, prosthodontist, clinical geneticist, cardiologist, pulmonologist, orthopaedician, urologist, psychologist, pediatrician, and pediatric neurologist.

References

1. Veena KM, Jagadishchandra H, Rao PK, Chatra L. Ellis-van Creveld syndrome in an Indian child: a case report. *Imaging Sci Dent* 2011; 41(4):167-70.
2. Kunderagi NG, Taori K, Kumawat R, Rathod J, Sawant AE. Ellis van creveld syndrome with synpolydactyly, an antenatal diagnosis with postnatal correlation. *J Clin Imaging Sci* 2011;1:59.
3. Rudnik-Schöneborn S, Zerres K, Graul-Neumann L. Two Adult Patients with Ellis-van Creveld Syndrome Extending the Clinical Spectrum. *Mol Syndromol* 2011;1(6):301-06

From the Deptt. of Endocrinology and *Radiology, Sheri Kashmir Institute of Medical Sciences, Soura, Srinagar J&K- India
Correspondence to : Dr. M. Nasir Shamas, Senior Resident, Deptt. of Endocrinology, Sheri Kashmir Institute of Medical Sciences, Soura, Srinagar J&K